

## HISTORY OF PROFOH

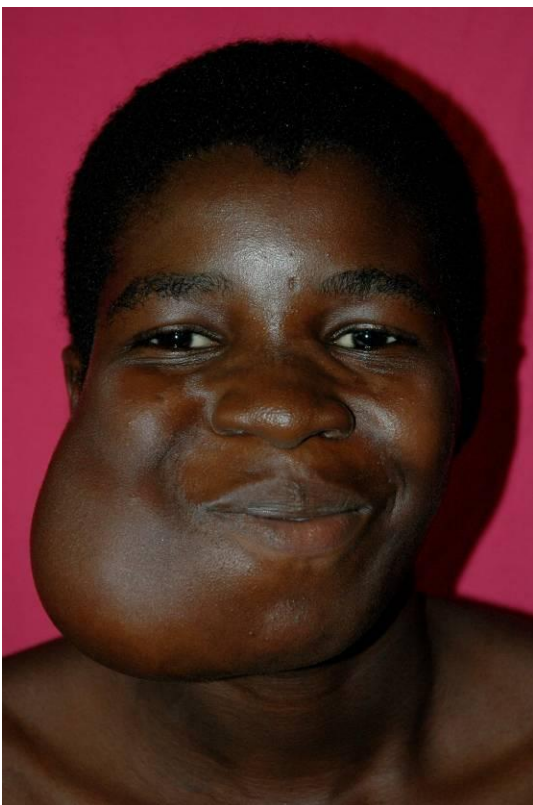Some Twenty ago, some group of friends under the leadership of an American who was the Administrator of Nigerian Christain Hospital, Aba State-Nigeria, Cliff Henry Jarrell made a life changing decision. At the time, in 1995, a series of fortuitous event happened in West Africa including the outbreak of epidemic in Kano,Nigeria ultimately PROFESSIONALS FOR HUMANITY (PROFOH) was born, What a great decision! Dr Prosper,Dr Lawrence and Dr Quartemont who was also with us spiritually as he has gone back to the United States after three Years of painful yet sefless service to Nigeria with his young wife Velvet, these people proved to be a great persons, a great medical doctors, and great mentor. The know almost and could do anything in health care delivery. I came back to Nigeria in 1997 after my training in Germany and Czech Republic trying to become a medical person like them, i ended up as medical micro biology, my wife was the first person that exposed me to the additional training ,few years later Dr Quartemont trained to be a theatre nurse.

From 1998 when PROFOH was established to 2011, conducted several medical and Social missions across West Africa ,Ghana, Nigeria, Liberia, Ethiopia ,etc we have performed surgeries for thousands and clinical consultations is hundred of thousands,and a lot social work with every professional, including high school students, college students, medical students, activists, nurses, respiratory therapists, surgical residents, veterinarians, and lawyers. In recent years, my teams have been composed exclusively of local healthcare providers from all parts of Nigeria. And have also fighting corruption in the complex health sector. We are registered in Nigeria, Ghana, Germany and the United States, registration process is on-going in Benin, Liberia, Cameroon and United Kingdom.

G. D. Kama

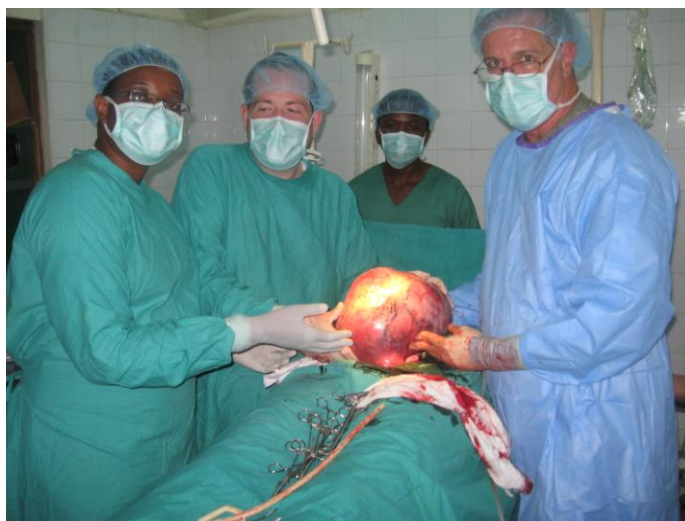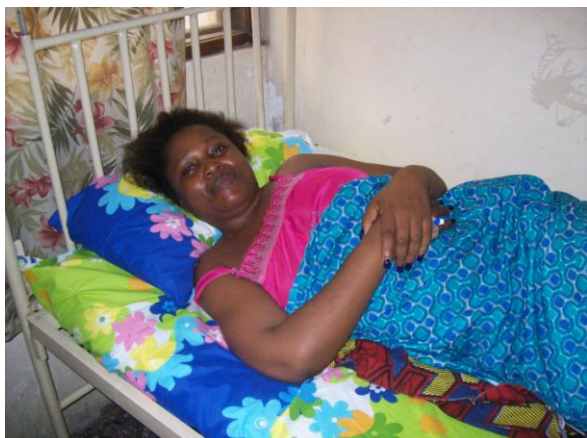Executive Director.

## SOME OF OUR WORK IN A GLANCE

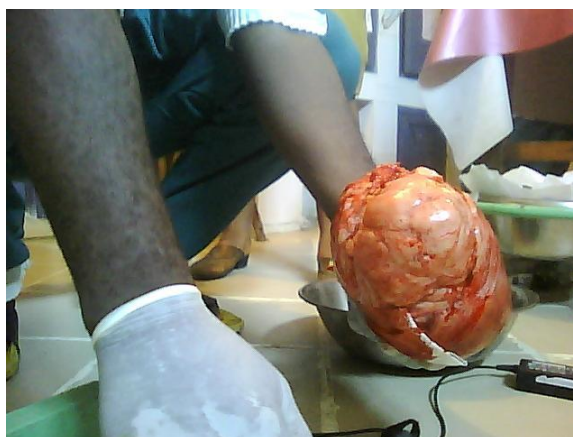
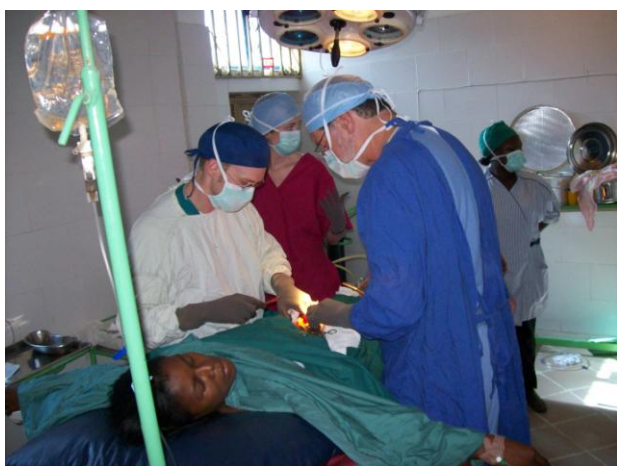

Miss Rose Before and After picture

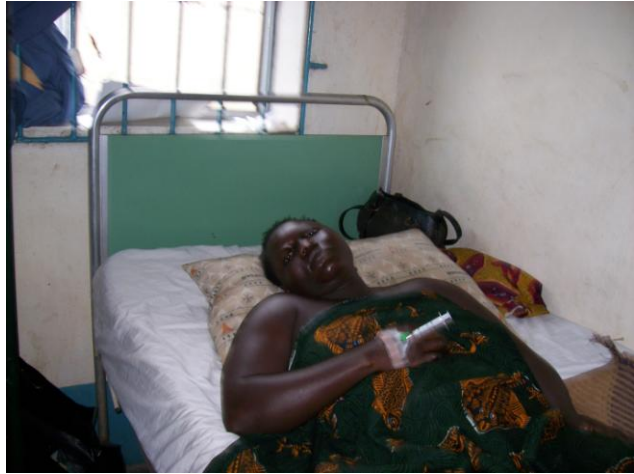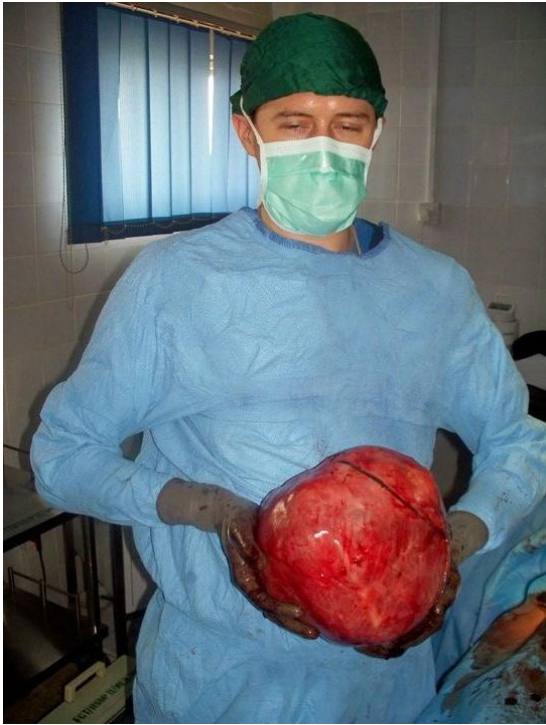The after is about 7 weeks after surgery right hemimandibulectomy for a mural ameloblastoma. she is eating and speaking fine.



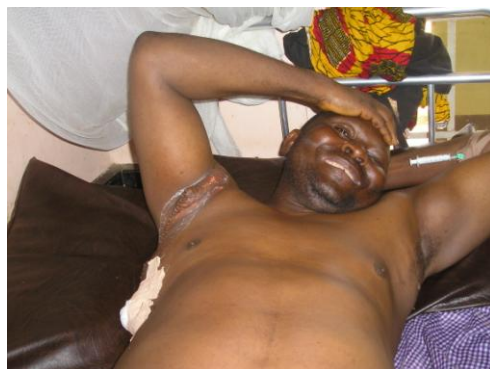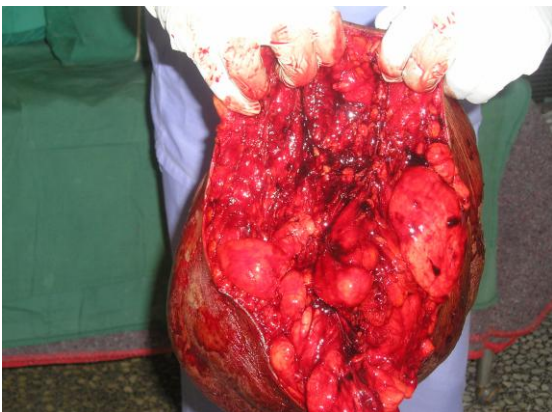
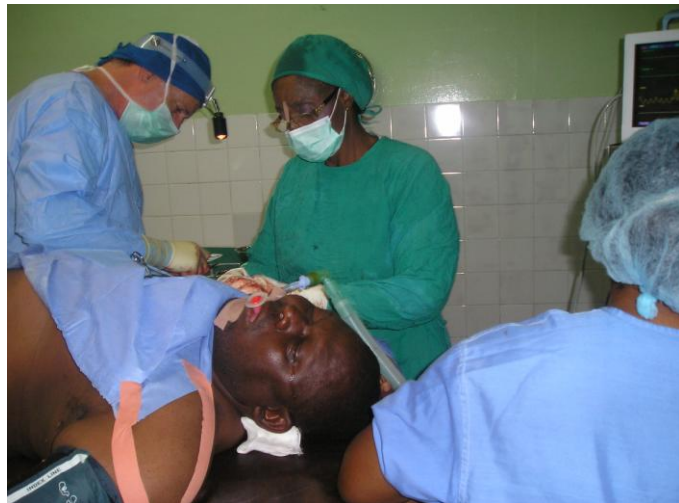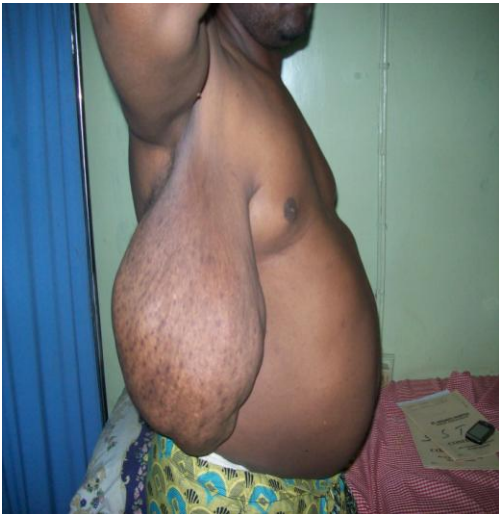Recheal and Udeme New Mile One Hospital and Bosom Clinic Port Harcourt May/Sept 2011





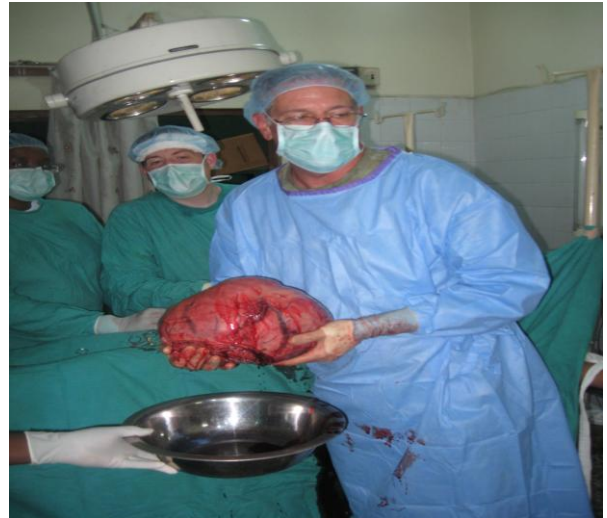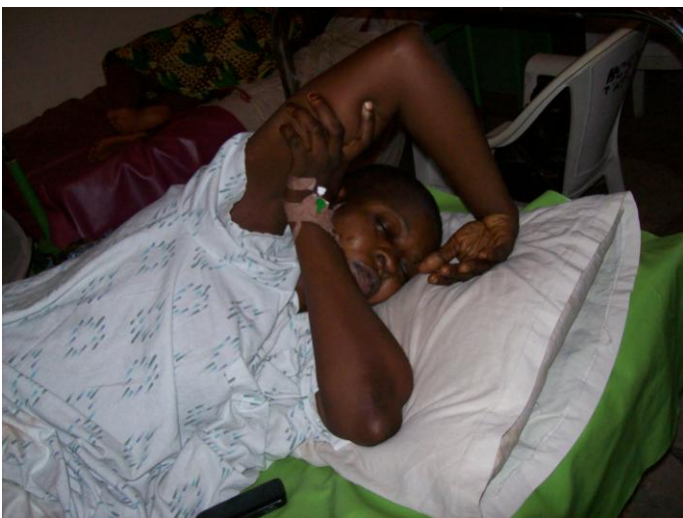

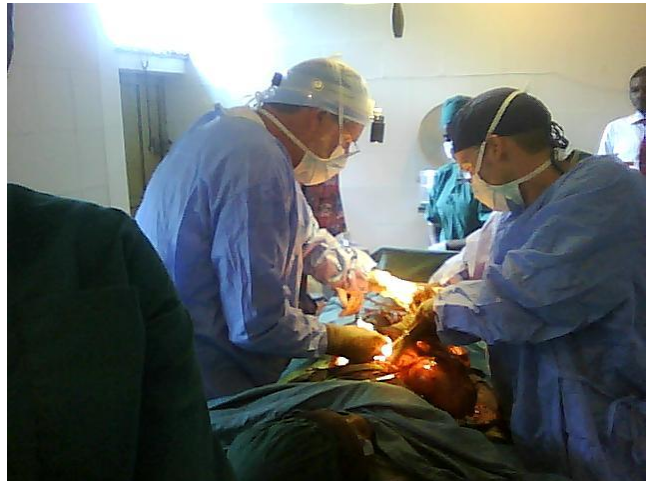
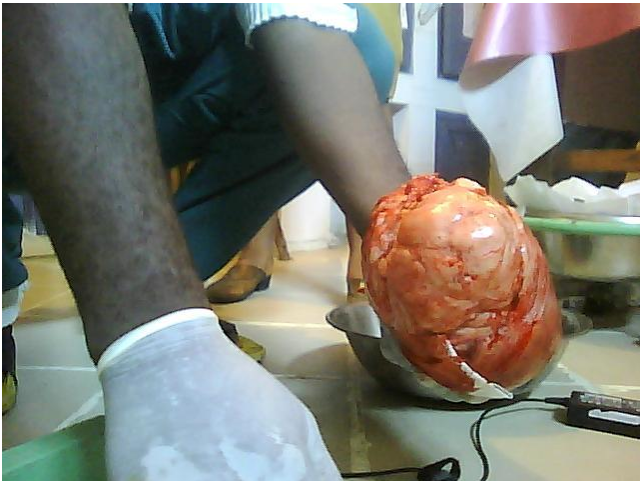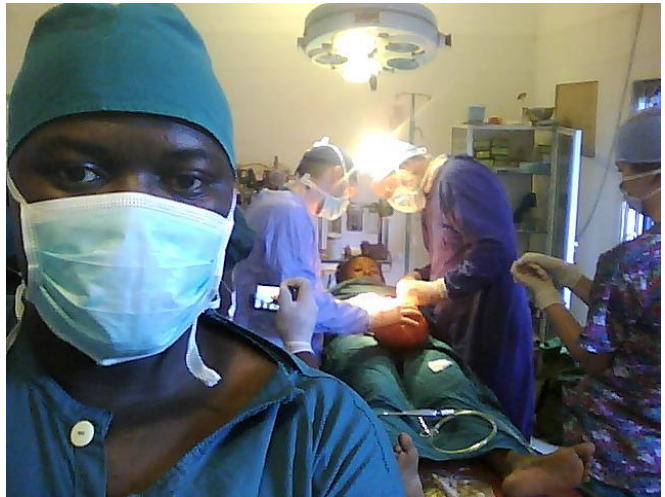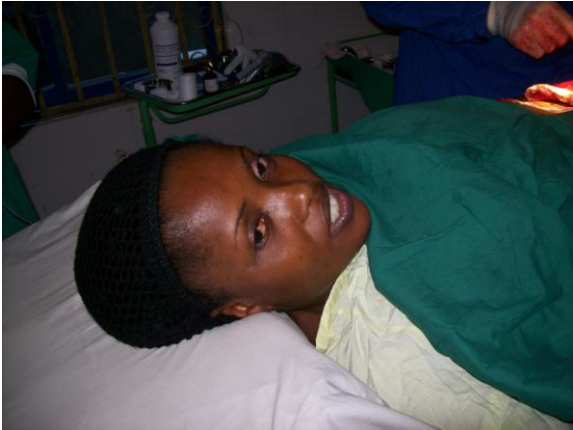Gida Mangoro Comprehensive Hospital Abuja, Pillow size fibroid. Below is Mr Ujah with Neurofibromatosis of 15yrs





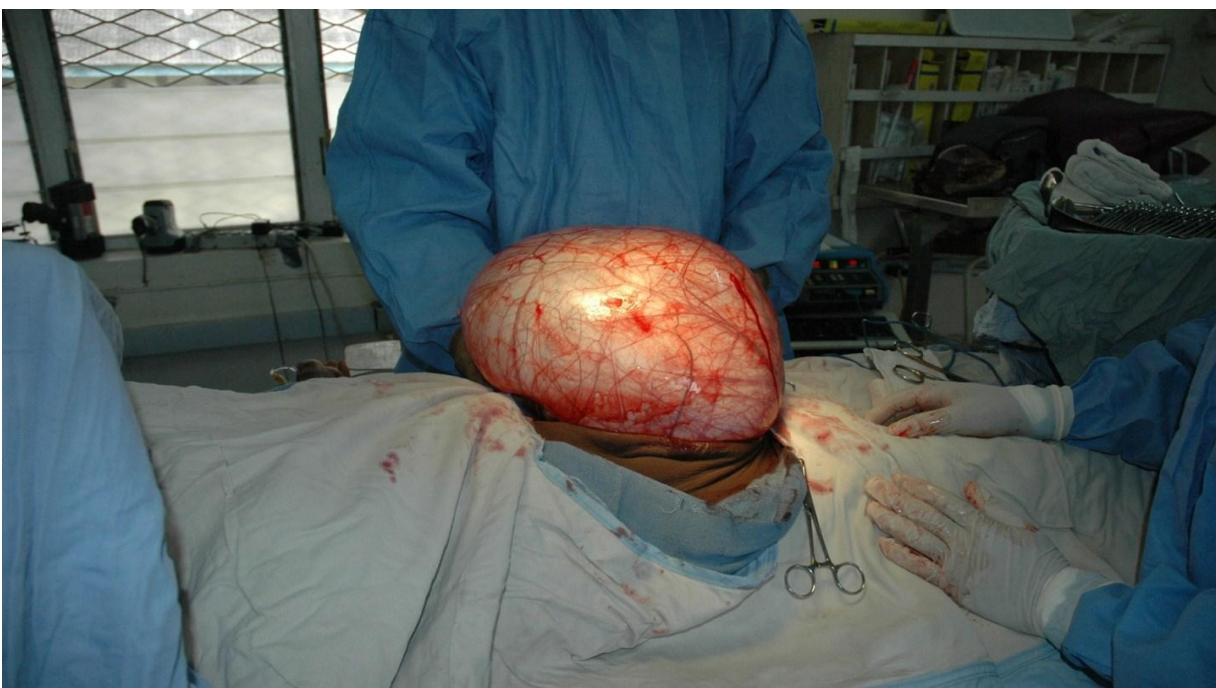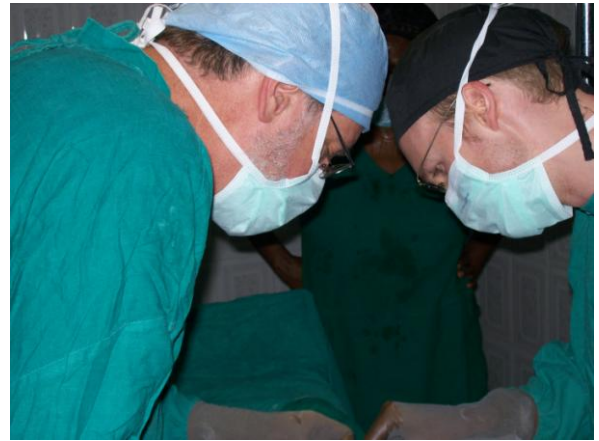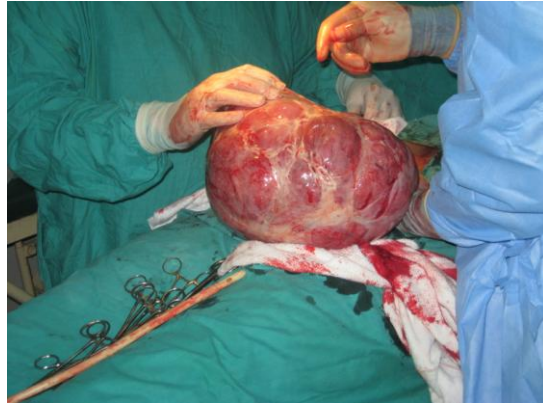We performed several hysterectomies on women with prolapsed uteruses



Betty husband left her because of this fibroid; we hope the man comes back

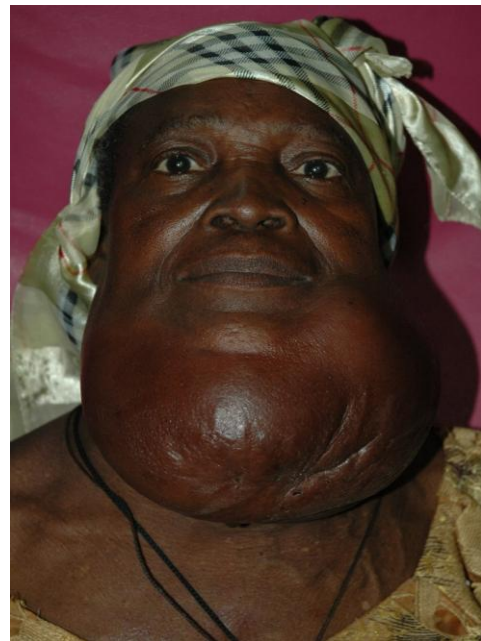
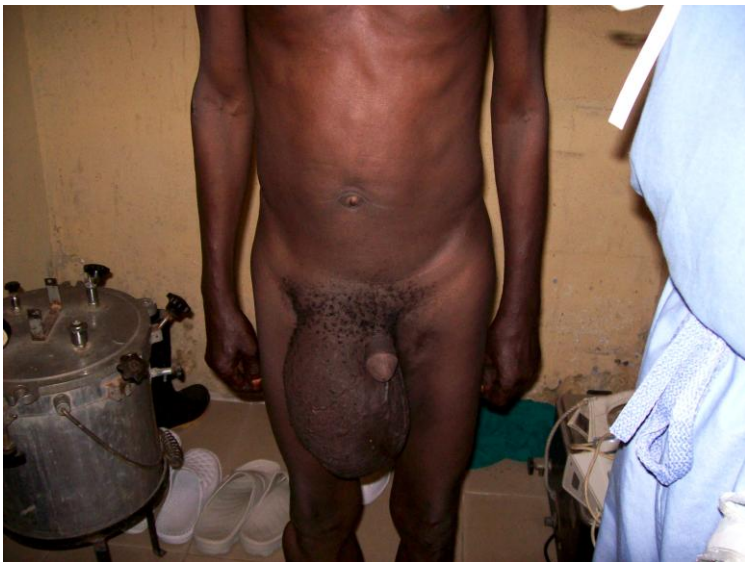

This woman said, "you gave me life after 15 years of Fibroid pregnancy"



Ovarian cyst





Joseph & Joy saved their giant hernia and goiter for six years because he could not afford N30,000 for the surgery- until PROFOH found them.



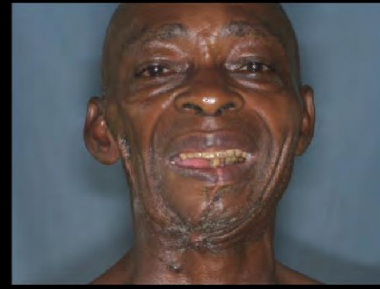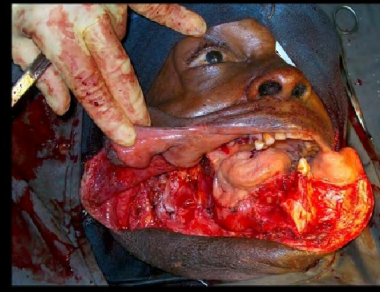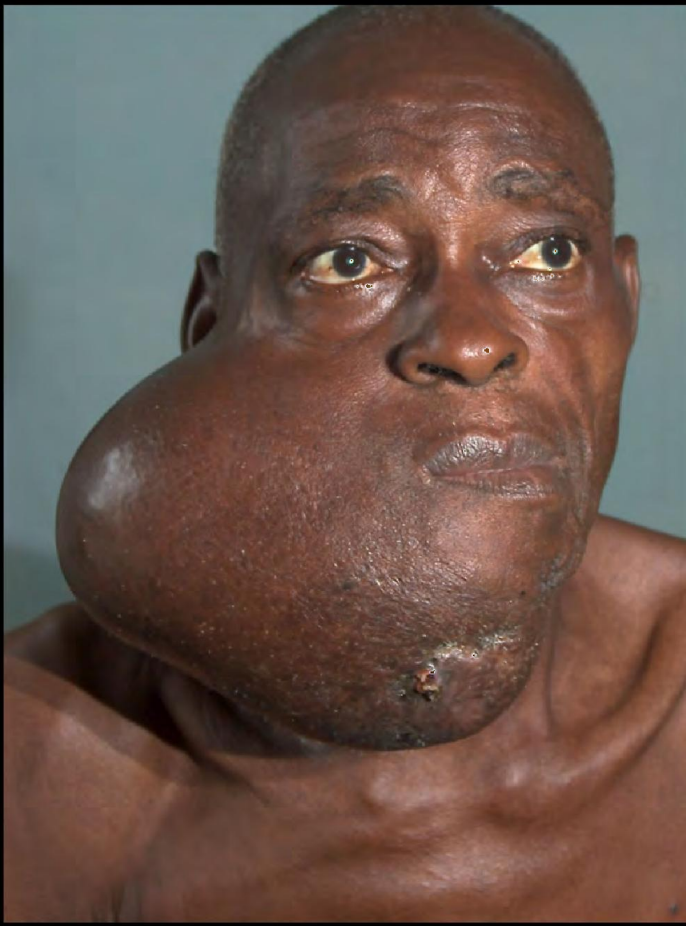The 1<sup>st</sup> Lady of Rivers State, Mrs J. Ameachi Paid us a courtesy visit and invited us to Government House the next day for Dinner.





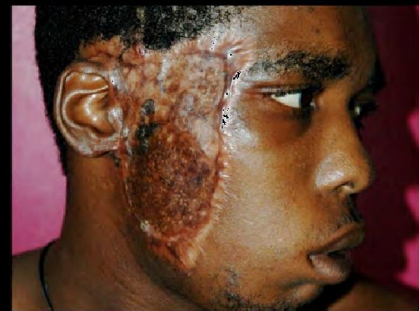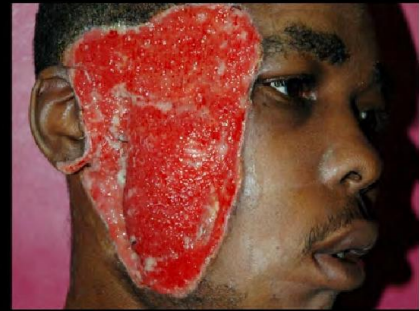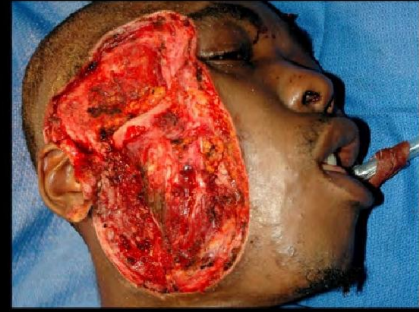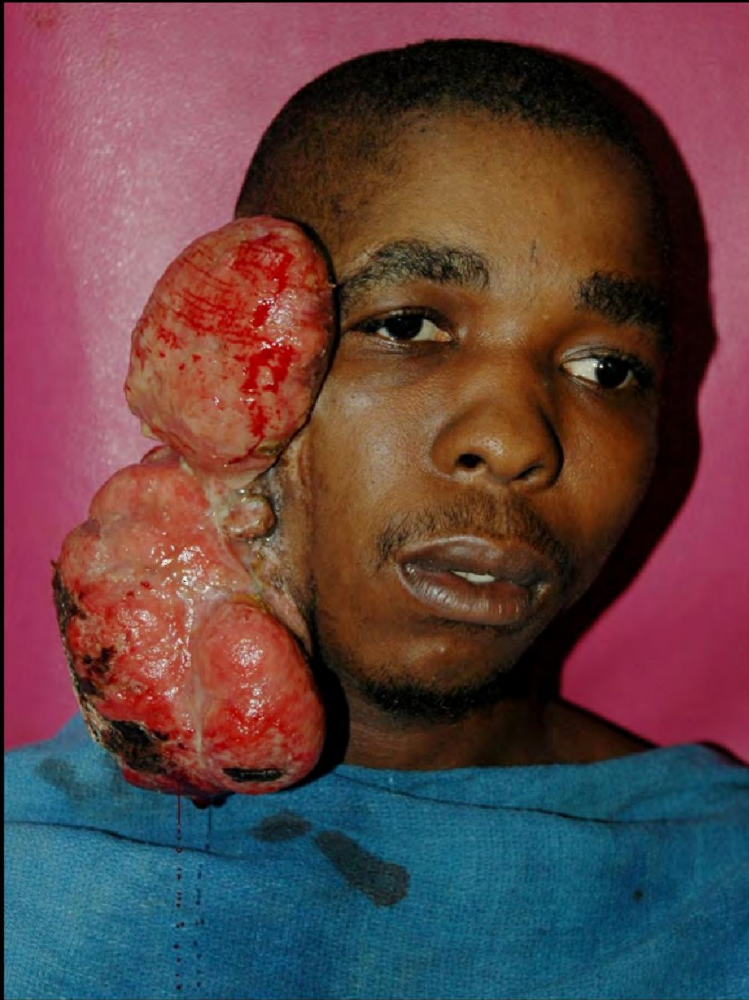PROFOH adopted Orphanage home June 2011 team playing games with the Children. Velvet Quartemont leader of the team.





We met Robert in 2004 He had a massive jaw tumor that had had been growing for a decade. He had a previous surgery but the tumor recurred and he gave up hope of a cure. The tumor was an ameloblastoma, a tumor of odontogenic origin (referring to teeth formation) that expands the mandible (jaw) from the inside. In Robert's case, the hollowed out mandible became infected and developed a sinus to the skin (see the lowest portion of the chin). Every time he coughed or sneezed, pus would gush out of the sinus. It was a terrible way to live .We resected the tumor, which required removing half of his mandible, and did a pectoralis major muscle flap to help with reconstruction and closure. He is still doing well, without recurrence for now, 2011.An interesting side to this wonderful story is that Robert's daughter (picture below) went to medical school. She had financial difficulties and almost had to quit. Dr Brian Camazine (the surgoen who peformed the surgery) and his sister Alisse Camazine, supported her education. She completed her schooling in 2010.





We Innocent Eyor in February of 2011. He is a young male that had a huge mass growing from the right side of his face for years. He had been to several medical centers but the surgeons refused to operate-either the surgeons lacked the required skills or the patient lacked the required funds. The tumor was quite spectacular. Each time Innocent removed the dressings covering the tumor, blood squirted from the bottom. As a result, Innocent was anemic as well as malnourished. We rapidly removed the tumor and controlled the bleeding. The wound did not start granulating until we bought Innocent 6 eggs per day for two weeks! Then we skin grafted the wound. The pathology showed a dermatofibrosarcoma protuberans (DFSP)-fibrosarcomatous variant. This tumor is a rare soft tissue sarcoma that is usually not malignant but tends to recur locally-especially if the surgical margins are close to the tumor. The fibrosarcomatous variant is more malignant. Unfortunately for Innocent, the margins were very close (since we could not remove his head) and the pathology worrisome. As a result, he will need radiation therapy. Of course, radiation therapy is difficult in Nigeria. There are only 2-3 sites that do this treatment and it is costly. Innocent will have to travel to Zaria, in Northern Nigeria.